



An Independent Licensee of the Blue Cross Blue Shield Association

PHARMACY COVERAGE GUIDELINES  
SECTION: DRUGS

ORIGINAL EFFECTIVE DATE: 1/22/2015  
LAST REVIEW DATE: 8/19/2021  
LAST CRITERIA REVISION DATE: 5/19/2022  
ARCHIVE DATE:

---

## ESBRIET® (pirfenidone) oral OFEV® (nintedanib) oral Pirfenidone oral

---

Coverage for services, procedures, medical devices and drugs are dependent upon benefit eligibility as outlined in the member's specific benefit plan. This Pharmacy Coverage Guideline must be read in its entirety to determine coverage eligibility, if any.

This Pharmacy Coverage Guideline provides information related to coverage determinations only and does not imply that a service or treatment is clinically appropriate or inappropriate. The provider and the member are responsible for all decisions regarding the appropriateness of care. Providers should provide BCBSAZ complete medical rationale when requesting any exceptions to these guidelines.

The section identified as “Description” defines or describes a service, procedure, medical device or drug and is in no way intended as a statement of medical necessity and/or coverage.

The section identified as “Criteria” defines criteria to determine whether a service, procedure, medical device or drug is considered medically necessary or experimental or investigational.

State or federal mandates, e.g., FEP program, may dictate that any drug, device or biological product approved by the U.S. Food and Drug Administration (FDA) may not be considered experimental or investigational and thus the drug, device or biological product may be assessed only on the basis of medical necessity.

Pharmacy Coverage Guidelines are subject to change as new information becomes available.

For purposes of this Pharmacy Coverage Guideline, the terms "experimental" and "investigational" are considered to be interchangeable.

BLUE CROSS®, BLUE SHIELD® and the Cross and Shield Symbols are registered service marks of the Blue Cross and Blue Shield Association, an association of independent Blue Cross and Blue Shield Plans. All other trademarks and service marks contained in this guideline are the property of their respective owners, which are not affiliated with BCBSAZ.

---

This Pharmacy Coverage Guideline does not apply to FEP or other states' Blues Plans.

Information about medications that require precertification is available at [www.azblue.com/pharmacy](http://www.azblue.com/pharmacy).

Some large (100+) benefit plan groups may customize certain benefits, including adding or deleting precertification requirements.

All applicable benefit plan provisions apply, e.g., waiting periods, limitations, exclusions, waivers and benefit maximums.

Precertification for medication(s) or product(s) indicated in this guideline requires completion of the [request form](#) in its entirety with the chart notes as documentation. **All requested data must be provided.** Once completed the form must be signed by the prescribing provider and faxed back to BCBSAZ Pharmacy Management at (602) 864-3126 or emailed to [Pharmacyprecert@azblue.com](mailto:Pharmacyprecert@azblue.com). **Incomplete forms or forms without the chart notes will be returned.**

---

## ESBRIET® (pirfenidone) oral OFEV® (nintedanib) oral Pirfenidone oral

---

### Criteria:

#### Section A. Idiopathic Pulmonary Fibrosis (IPF):

#### ESBRIET (pirfenidone)

#### OFEV (nintedanib)

#### Pirfenidone

- **Criteria for initial therapy:** Esbriet (pirfenidone), Ofev (nintedanib) or generic pirfenidone is considered **medically necessary** and will be approved when **ALL** of the following criteria are met:
1. Prescriber is a physician specializing in the patient's diagnosis or is in consultation with a Pulmonologist
  2. Individual is 18 years of age or older
  3. A confirmed diagnosis of idiopathic pulmonary fibrosis (IPF) by **ONE** of the following:
    - a. Findings on high-resolution computed tomography (HRCT), performed within the last 12 months, indicating usual interstitial pneumonia (UIP), a copy of HRCT must be submitted (See Table 1)
    - b. If performed, a surgical lung biopsy demonstrating usual interstitial pneumonia (UIP), a copy must be submitted (See Tables 2 & 3)
    - c. Specific HRCT and lung biopsy combinations, as per histopathological criteria for UIP pattern and HRCT and biopsy patterns, in patients with surgical lung biopsy, a copy of HRCT & biopsy results must be submitted (See Table 4)
  4. Individual is a nonsmoker or has been abstinent from smoking for at least six weeks or is participating in a smoking cessation program
  5. Pulmonary function tests with evidence of **EITHER** of the following: (a copy of tests must be submitted)
    - a. Most recent tests show **BOTH** of the following:
      - i. FVC is  $\geq$  50% of the predicted value
      - ii. DLCO is 30-79% of predicted value
    - b. Longitudinal changes in the last six month show **EITHER** of the following:
      - i. Decline in absolute FVC of 5-10%
      - ii. Decline in absolute DLCO of 10-15%
  6. There are no significant interacting drugs
  7. Individual does not have hepatic impairment as defined below:
    - a. **For Esbriet (pirfenidone) or generic:** does not have severe hepatic impairment (Child-Pugh Class C)
    - b. **For Ofev (nintedanib):** does not have moderate or severe hepatic impairment (Child-Pugh B or C)

---

## ESBRIET® (pirfenidone) oral OFEV® (nintedanib) oral Pirfenidone oral

---

8. Esbriet (pirfenidone) and Ofev (nintedanib) will not be used simultaneously
9. Individual does not have renal impairment as defined below:
  - a. **For Esbriet (pirfenidone) or generic:** does not have end-stage renal disease requiring dialysis
  - b. **For Ofev (Nintedanib):** does not have severe renal impairment (CrCl < 30 mL/min) or end-stage renal disease
10. **ALL** of the following baseline tests have been completed before initiation of treatment:
  - a. Liver function testing within the last 30 days
  - b. Renal function testing within the last 30 days
  - c. **Additionally, for Ofev (nintedanib):** a negative pregnancy test in a woman of child bearing age, unless is using effective contraception

**Initial approval duration:** 6 months

- **Criteria for continuation of coverage (renewal request):** Esbriet (pirfenidone), Ofev (nintedanib) or generic pirfenidone is considered **medically necessary** and will be approved when **ALL** of the following criteria are met:
1. Individual continues to be seen by a physician specializing in the patient's diagnosis or is in consultation with a Pulmonologist
  2. Individual's condition has responded while on therapy
    - a. Response is defined as **TWO** of the following:
      - i. Significant improvement in %FVC over baseline
      - ii. Absolute decline in FVC is less than 10%
      - iii. Absolute decline in DLCO is less than 15%
      - iv. Improved or no decline in symptoms for cough or shortness of breath
  3. Individual is a nonsmoker or is participating in a smoking cessation program
  4. Individual has been adherent with the medication
  5. Individual has not developed any significant adverse drug effects that may exclude continued use
    - a. Significant adverse effect such as:
      - i. Liver toxicity
      - ii. Severe and persistent GI reactions
  6. Esbriet (pirfenidone) or generic pirfenidone and Ofev (nintedanib) will not be used simultaneously
  7. There are no significant interacting drugs

**Renewal duration:** 12 months

---

## ESBRIET® (pirfenidone) oral OFEV® (nintedanib) oral Pirfenidone oral

---

➤ Criteria for a request for non-FDA use or indication, treatment with dosing, frequency, or duration outside the FDA-approved dosing, frequency, and duration, refer to one of the following Pharmacy Coverage Guideline:

1. **Off-Label Use of Non-Cancer Medications**
  2. **Off-Label Use of Cancer Medications**
- 

### **Section B. Systemic Sclerosis-associated Interstitial Lung Disease (SSc-ILD):** **OFEV (nintedanib)**

➤ **Criteria for initial therapy:** Ofev (nintedanib) is considered *medically necessary* and will be approved when **ALL** of the following criteria are met:

1. Prescriber is a physician specializing in the patient's diagnosis or is in consultation with a Pulmonologist or Rheumatologist
2. Individual is 18 years of age or older
3. A confirmed diagnosis of by of the following:
  - a. Systemic sclerosis-Interstitial lung disease as defined by American College of Rheumatology/European League Against Rheumatism ([See Definitions section Tables 6 & 7](#))
  - b. Disease onset (first non-Raynaud symptom) is less than 7 years
  - c. High resolution computed tomography (HRCT) scan within the previous 12 months shows  $\geq$  10% fibrosis
  - d. FVC is  $\geq$  40% of the predicted value
  - e. DLCO is 30-89% of predicted value
4. Individual is a nonsmoker or has been abstinent from smoking for at least six weeks or is participating in a smoking cessation program
5. Individual does not have moderate or severe hepatic impairment (Child-Pugh B or C)
6. Individual does not have severe renal impairment (CrCl < 30 mL/min) or end-stage renal disease
7. There are no significant interacting drugs
8. Esbriet (pirfenidone) or generic pirfenidone and Ofev (nintedanib) will not be used simultaneously
9. **ALL** of the following baseline tests have been completed before initiation of treatment:
  - a. Liver function testing within the last 30 days
  - b. Renal function testing within the last 30 days

---

## ESBRIET® (pirfenidone) oral OFEV® (nintedanib) oral Pirfenidone oral

---

c. A negative pregnancy test in a woman of child bearing age, unless is using effective contraception

**Initial approval duration:** 6 months

- **Criteria for continuation of coverage (renewal request):** Ofev (nintedanib) is considered *medically necessary* and will be approved when **ALL** of the following criteria are met:
1. Individual continues to be seen by a physician specializing in the patient's diagnosis or is in consultation with a Pulmonologist or Rheumatologist
  2. Individual's condition has responded while on therapy
    - a. Response is defined as **TWO** of the following:
      - i. Significant improvement in %FVC over baseline
      - ii. Absolute decline in FVC is less than 10%
      - iii. Absolute decline in DLCO is less than 15%
      - iv. Improved or no decline in symptoms for cough or shortness of breath
  3. Individual is a nonsmoker or is participating in a smoking cessation program
  4. Esbriet (pirfenidone) or generic pirfenidone and Ofev (nintedanib) will not be used simultaneously
  5. Individual has been adherent with the medication
  6. Individual has not developed any significant adverse drug effects that may exclude continued use
    - a. Significant adverse effect such as:
      - i. Liver toxicity
      - ii. Severe and persistent GI reactions
  7. There are no significant interacting drugs

**Renewal duration:** 12 months

- Criteria for a request for non-FDA use or indication, treatment with dosing, frequency, or duration outside the FDA-approved dosing, frequency, and duration, refer to one of the following Pharmacy Coverage Guideline:
1. **Off-Label Use of Non-Cancer Medications**
  2. **Off-Label Use of Cancer Medications**

---

**ESBRIET® (pirfenidone) oral**  
**OFEV® (nintedanib) oral**  
**Pirfenidone oral**

---

**Section C. Chronic Fibrosing Interstitial Lung Disease with a Progressive Phenotype:**  
**OFEV (nintedanib)**

- **Criteria for initial therapy:** Ofev (nintedanib) is considered *medically necessary* and will be approved when **ALL** of the following criteria are met:
1. Prescriber is a physician specializing in the patient's diagnosis or is in consultation with a Pulmonologist or Rheumatologist
  2. Individual is 18 years of age or older
  3. A confirmed diagnosis of chronic fibrosing interstitial lung disease with a progressive phenotype by **ONE** of the following:
    - a. Clinically significant decrease in FVC % predicted of  $\geq 10\%$
    - b. Decline of FVC % predicted of  $\geq 5\%$  but  $<10\%$  with worsening respiratory symptoms or with worsening fibrosis on chest imaging
    - c. Worsening of respiratory symptoms and with worsening fibrosis on chest imaging
  4. Baseline FVC  $\geq 45\%$  predicted
  5. Baseline DLCO  $\geq 30\%$  and  $< 80\%$  of predicted
  6. Individual is a nonsmoker or has been abstinent from smoking for at least six weeks or is participating in a smoking cessation program
  7. Individual does not have moderate or severe hepatic impairment (Child-Pugh B or C)
  8. Individual does not have severe renal impairment (CrCl  $< 30$  mL/min) or end-stage renal disease
  9. There are no significant interacting drugs
  10. Esbriet (pirfenidone) or generic pirfenidone and Ofev (nintedanib) will not be used simultaneously
  11. **ALL** of the following baseline tests have been completed before initiation of treatment:
    - a. Liver function testing within the last 30 days
    - b. Renal function testing within the last 30 days
    - c. A negative pregnancy test in a woman of child bearing age, unless is using effective contraception

**Initial approval duration:** 6 months

---

## ESBRIET® (pirfenidone) oral OFEV® (nintedanib) oral Pirfenidone oral

---

- **Criteria for continuation of coverage (renewal request):** Ofev (nintedanib) is considered *medically necessary* and will be approved when **ALL** of the following criteria are met:
1. Individual continues to be seen by a physician specializing in the patient's diagnosis or is in consultation with a Pulmonologist or Rheumatologist
  2. Individual's condition has responded while on therapy
    - a. Response is defined as **TWO** of the following:
      - i. Improvement in %FVC over baseline or reduced rate of decline in FVC
      - ii. No worsening or development of dyspnea
      - iii. No new changes on imaging
  3. Individual is a nonsmoker or is participating in a smoking cessation program
  4. Esbriet (pirfenidone) or generic pirfenidone and Ofev (nintedanib) will not be used simultaneously
  5. Individual has been adherent with the medication
  6. Individual has not developed any significant adverse drug effects that may exclude continued use
    - a. Significant adverse effect such as:
      - i. Liver toxicity
      - ii. Severe and persistent GI reactions
  7. There are no significant interacting drugs

**Renewal duration:** 12 months

- Criteria for a request for non-FDA use or indication, treatment with dosing, frequency, or duration outside the FDA-approved dosing, frequency, and duration, refer to one of the following Pharmacy Coverage Guideline:
1. **Off-Label Use of Non-Cancer Medications**
  2. **Off-Label Use of Cancer Medications**
- 

### **Description:**

Esbriet (pirfenidone) & Ofev (nintedanib) are approved for the treatment of idiopathic pulmonary fibrosis (IPF), a specific form of chronic progressive interstitial lung disease of the lower respiratory tract in which lung tissue becomes scarred or fibrotic over time. Ofev (nintedanib) is also indicated for patients with systemic sclerosis-associated interstitial lung disease (SSc-ILD) to slow the rate of decline in pulmonary function. Ofev (nintedanib) is indicated for the treatment of chronic fibrosing interstitial lung diseases (ILDs) with a progressive phenotype.

---

## ESBRIET® (pirfenidone) oral OFEV® (nintedanib) oral Pirfenidone oral

---

Esbriet (pirfenidone) exact mechanism of action is unknown, however, pirfenidone has anti-inflammatory and anti-fibrotic activity. Pirfenidone exerts anti-inflammatory effects by interfering with the production of transforming growth factor (TGF)-beta (involved in cell growth) and tumor necrosis factor (TNF)-alpha (involved in inflammation). It acts as an antifibrotic agent by altering the expression, synthesis, and possibly accumulation of collagen. Esbriet (pirfenidone) is available as 267 mg capsule or tablet and 801 mg tablet.

Ofev (nintedanib) is a tyrosine kinase inhibitor that reduces fibroblast activity by binding to receptors for various growth factors, including vascular endothelial growth factor (VEGF), platelet-derived growth factor (PDGF) and fibroblast growth factor (FGF). These pathways are implicated in the scarring of lung tissue. It blocks intracellular signaling, preventing proliferation, migration, transformation of fibroblasts implicated in IPF pathogenesis.

### Idiopathic Pulmonary Fibrosis (IPF)

IPF, also known as cryptogenic fibrosing alveolitis (CFA), is a specific and the most common type of idiopathic chronic, fibrosing interstitial pneumonia (IIP). IPF is defined as a specific form of chronic, progressive fibrosing of IIP unknown cause. IIPs are spontaneously occurring diffuse parenchymal lung diseases. Other IIPs include nonspecific interstitial pneumonia (NSIP), desquamative interstitial pneumonia (DIP), respiratory bronchiolitis associated interstitial lung disease (RB-ILD), acute interstitial pneumonia (AIP), lymphocytic interstitial pneumonia (LIP), and cryptogenic organizing pneumonia (COP). IIPs are classified based on their histopathologic appearances.

IPF is a progressive disease characterized by an irreversible decline in pulmonary function, worsening of pulmonary symptoms, and progressive fibrosis on high-resolution computed tomography (HRCT). As a result, patients with IPF experience shortness of breath, cough, and have difficulty participating in everyday physical activities. The exact cause of IPF is not known, but associated risk factors include cigarette smoking, viral infection, environmental pollutants, chronic aspiration, genetic predisposition, and drugs.

IPF is a fatal lung disease with a variable and unpredictable course, in which progression occurs slowly in the majority of patients; a minority of patients experience rapid progression or stable disease, some experience episodes of acute respiratory worsening despite previous stability. The prognosis of IPF is poor, with only 20-30% of individuals are alive five years after diagnosis. Hospitalizations for respiratory problems are common and are frequently associated with death. No medication has been found to cure IPF, but nintedanib and pirfenidone, have been shown to slow disease progression, as evidenced by smaller decline in FVC, compared to placebo in adult patients with IPF.

Cigarette smoking is most strongly associated with IPF. Exposure to stone, metal, wood, and organic dusts has also been suggested as a risk factor as well as gastroesophageal reflux disease.

HRCT should be obtained in all patients suspected of having IPF. The presence of certain specific HRCT features in the appropriate clinical setting, may be sufficient to establish the diagnosis.

The characteristic HRCT features of IPF include peripheral (subpleural), bibasilar reticular opacities associated with architectural distortion, including honeycomb changes and traction bronchiectasis. While honeycombing is essential to making a definite diagnosis, it may be absent.



---

## ESBRIET® (pirfenidone) oral OFEV® (nintedanib) oral Pirfenidone oral

---

When the results of the clinical evaluation, laboratory testing, and HRCT do not allow for a confident diagnosis of IPF, lung biopsy may be indicated. When performed, lung biopsy results need to be correlated with the HRCT findings. For patients who require histopathologic confirmation of IPF, a surgical biopsy is preferred over transbronchial lung biopsy (TBLB).

The diagnosis of IPF requires exclusion of other known causes of ILD AND either definite features of UIP on HRCT or certain combinations of HRCT and lung biopsy features of UIP. The histologic hallmark and chief diagnostic criterion for UIP is a heterogeneous appearance with alternating areas of normal lung, interstitial inflammation, fibroblast foci, and honeycomb changes. A UIP-like pattern of injury can also be seen in other fibrotic lung diseases, such as those associated with rheumatic diseases, chronic hypersensitivity pneumonitis, drug-toxicity, and pneumoconioses, such as asbestosis

There is no staging system for assessing the severity of IPF. Patients progress from mild to moderate to severe respiratory limitation. Disease severity is assessed on the basis of symptoms, HRCT, and pulmonary function testing. Surrogate markers for the disease include forced vital capacity (FVC) and diffusing capacity of the lung for carbon monoxide (DLCO). Use of the FVC as an efficacy measure is both supported and discouraged in the literature while the DLCO is considered a standard predictor of survival.

Moderate disease is characterized by: non-productive cough, dyspnea on moderate exertion (supplemental oxygen may be needed with exertion), and mild-to-moderate pulmonary function abnormalities: reduced FVC (50-70% of predicted), reduced DLCO (45-65% of predicted), and/or  $P(A-a)O_2$  (21-30 mmHg).

Advanced disease is characterized by: dyspnea on mild exertion (walking < 300 feet or climbing more than one flight of stairs), oxygen desaturation ( $\geq 4\%$ ) during a six-minute walk test, requires supplemental oxygen at rest and/or with exertion, and moderate to severe pulmonary function abnormalities: reductions in FVC (< 50% of predicted), reductions in DLCO (< 50% of predicted), and  $P(A-a)O_2$  difference elevated (> 30 mmHg).

Clinical features associated with increased risk of mortality include: level of dyspnea, increasing degree of dyspnea, absolute decrease in FVC by  $\geq 10\%$ , absolute decrease in DLCO by  $\geq 15\%$ , DLCO < 40% of predicted, oxygen desaturation to  $\leq 88\%$  during a 6-minute walk test (6MWT), extent of honeycombing on HRCT, and worsening fibrosis on HRCT

IPF is defined by the American Thoracic Society in the following manner: a) exclusion of other known causes of interstitial lung disease (connective tissue disease, drug toxicity, domestic and occupational environmental exposure such as asbestos or beryllium exposure, hypersensitivity pneumonitis, systemic sclerosis, scleroderma, SLE, rheumatoid arthritis, radiation, sarcoidosis, bronchiolitis obliterans organizing pneumonia, HIV, viral hepatitis, or cancer) **and** b) presence of UIP pattern evidenced by HRCT alone or by a combination of surgical lung biopsy and HRCT.

### **Systemic sclerosis (SSc; scleroderma)**

Systemic sclerosis (SSc; scleroderma) is a connective tissue disease characterized by excessive collagen deposition, autoimmunity, and extensive vascular damage that involves multiple organs. It is believed to involve an abnormal response to microvascular injury in individuals with genetic susceptibility and/or epigenetic modifications, which leads to immune dysregulation, inflammation, microvasculopathy and fibrosis.

---

## **ESBRIET® (pirfenidone) oral OFEV® (nintedanib) oral Pirfenidone oral**

---

Systemic sclerosis is a heterogeneous disease with a pathogenesis characterized by three hallmarks: small vessel vasculopathy, production of autoantibodies, and fibroblast dysfunction leading to increased deposition of extracellular matrix. The clinical manifestations and the prognosis of SSc are variable, with the majority of patients having skin thickening and variable involvement of internal organs.

Patients with SSc are classified according to the extent of skin involvement: limited SSc (lSSc), with no detectable skin involvement; limited cutaneous SSc (lcSSc) with skin involvement limited to the hands and face; and diffuse SSc (dSSc), with skin involvement proximal to the elbows and knees.

In patients with lcSSc, visceral involvement is rare, and the prognosis is good, with the exception of the 8-12% of patients in whom pulmonary arterial hypertension (PAH), ILD and/or bowel involvement eventually occur. Patients with dSSc experience visceral involvement, which is responsible for reduced life expectancy. In addition to diminishing life expectancy, SSc is responsible for skin, tendon, joint, and vessel damage, which leads to disability, handicap, and worsening of quality of life. ILD is more frequently associated with dSSc. Since SSc associated ILD may develop in the absence of dyspnea, HRCT must be performed systematically in SSc patients, together with pulmonary function tests (PFT).

The histological pattern most commonly observed in SSc-ILD is nonspecific interstitial pneumonia (NSIP), observed in approximately two-thirds of patients. UIP is present in a minority of individuals with SSc-ILD. The extent of fibrosis on HRCT predicts the progression of ILD. Decline in lung function is also a predictor of mortality in patients with SSc-ILD.

### **Chronic Fibrosing Interstitial Lung Diseases with a Progressive Phenotype**

The term ILD includes a large group of more than 200 parenchymal pulmonary disorders that overlap in their clinical presentations and patterns of lung injury. A proportion of patients with ILDs develop a progressive-fibrosing phenotype. Progressive fibrosis is associated with worsening respiratory symptoms, decline in lung function, limited response to immunomodulatory therapies, decreased quality of life and, potentially, early death. IPF and several other ILDs may present a progressive-fibrosing phenotype. These may include

- Hypersensitivity pneumonitis
- Autoimmune ILDs: includes RA-associated ILD, mixed connective tissue disease, systemic sclerosis-associated ILD, and others
- Idiopathic nonspecific interstitial pneumonia
- Unclassifiable idiopathic interstitial pneumonia
- Other ILDs: includes fibrosing ILDs not categorized above such as occupational exposure-related ILD, sarcoidosis, and pleuro-parenchymal fibroelastosis

IPF is the most common ILD that is characterized by progressive fibrosis, lung scarring and a radiological pattern known as UIP.

**ESBRIET® (pirfenidone) oral**  
**OFEV® (nintedanib) oral**  
**Pirfenidone oral**

**Definitions:**

**Interstitial Lung Diseases:**

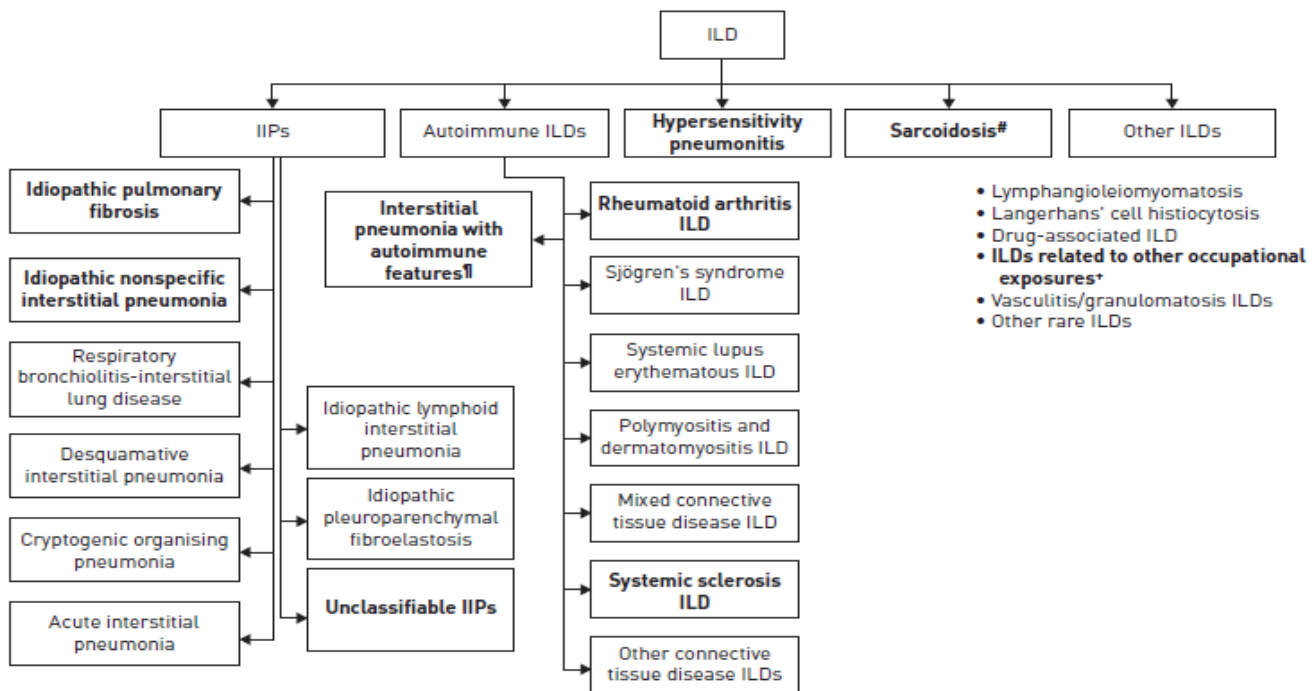


FIGURE 1 Types of interstitial lung disease (ILD) most likely to have a progressive-fibrosing phenotype [indicated in bold]. IIPs: idiopathic interstitial pneumonias. #: stage IV sarcoidosis only; †: not an established clinical diagnosis; \*: e.g. asbestosis, silicosis.

**Idiopathic Pulmonary Fibrosis (IPF) Criteria from the American Thoracic Society (ATS), the European Respiratory Society (ERS), the Japanese Respiratory Society (JRS), and the Latin American Thoracic Association (LATA):**

- Exclusion of other known causes of interstitial lung disease (for instance, domestic and occupational environmental exposures, connective tissue disease, and drug toxicity)
- Presence of a usual interstitial pneumonia (UIP) pattern on HRCT in patients without surgical lung biopsy, as evidenced by sub-pleural, basal predominance; reticular abnormality; honeycombing with or without traction bronchiectasis; and absence of any features inconsistent with UIP pattern. (See Table 1)
- Specific HRCT and lung biopsy combinations, as per histopathological criteria for UIP pattern and HRCT and biopsy patterns, in patients with surgical lung biopsy. (See Tables 2, 3, 4)

**PHARMACY COVERAGE GUIDELINES  
SECTION: DRUGS**

**ORIGINAL EFFECTIVE DATE: 1/22/2015  
LAST REVIEW DATE: 8/19/2021  
LAST CRITERIA REVISION DATE: 5/19/2022  
ARCHIVE DATE:**

**ESBRIET® (pirfenidone) oral  
OFEV® (nintedanib) oral  
Pirfenidone oral**

**HRCT Criteria for UIP Pattern:**

<b>Table 1: HRCT Criteria for UIP Pattern</b>	
<b>Pattern</b>	<b>Features</b>
UIP – need all 4 features	<ul style="list-style-type: none"> <li>• Sub-pleural, basal predominance</li> <li>• Reticular abnormality</li> <li>• Honeycombing with or without traction bronchiectasis</li> <li>• Absence of feature listed in Inconsistent with UIP (see below)</li> </ul>
Possible UIP – need all 3 features	<ul style="list-style-type: none"> <li>• Sub-pleural, basal predominance</li> <li>• Reticular abnormality</li> <li>• Absence of feature listed in Inconsistent with UIP (see below)</li> </ul>
Inconsistent with UIP – any of 7 features	<ul style="list-style-type: none"> <li>• Upper or mid-lung predominance</li> <li>• Peribronchovascular predominance</li> <li>• Extensive ground glass abnormality (extent &gt; reticular abnormality)</li> <li>• Profuse micronodules (bilateral, predominantly upper lobes)</li> <li>• Discrete cysts (multiple, bilateral, away from areas of honeycombing)</li> <li>• Diffuse mosaic attenuation/air-trapping (bilateral, in 3 or more lobes)</li> <li>• Consolidation in bronchopulmonary segment(s) / lobe(s)</li> </ul>

**Histologic features of UIP:**

<b>Table 2: Histologic features of UIP</b>	
<b>Key feature</b>	<b>Features</b>
Key feature	<ul style="list-style-type: none"> <li>• Dense fibrosis causing remodeling of lung architecture with frequent honeycomb fibrosis</li> <li>• Fibroblastic foci typically scattered at the edges of dense scars</li> <li>• Patchy lung involvement</li> <li>• Frequent subpleural and parseptal distribution</li> </ul>
Pertinent negative	<ul style="list-style-type: none"> <li>• Lack of active lesions of other interstitial diseases (such as sarcoidosis or Langerhans cell histiocytosis)</li> <li>• Lack of marked interstitial chronic inflammation</li> <li>• Granulomas are inconspicuous or absent</li> <li>• Lack of substantial inorganic dust deposits such as asbestos bodies (except for carbon black pigment)</li> <li>• Lack of marked eosinophilia</li> </ul>

**ESBRIET® (pirfenidone) oral**  
**OFEV® (nintedanib) oral**  
**Pirfenidone oral**

**Histological Criteria for UIP Pattern:**

<b>Table 3: Histologic Criteria for UIP Pattern from biopsy specimen</b>	
	Criteria
UIP Pattern – need all 4 criteria	<ul style="list-style-type: none"> <li>Evidence of marked fibrosis/architectural distortion, +/- honeycombing in a predominantly sub-pleural/paraseptal distribution</li> <li>Presence of patchy involvement of lung parenchyma by fibrosis</li> <li>Presence of fibroblast foci</li> <li>Absence of features against a diagnosis of UIP suggesting an alternate diagnosis (see Not UIP Pattern)</li> </ul>
Probable UIP Pattern	<ul style="list-style-type: none"> <li>Evidence of marked fibrosis/architectural distortion, +/- honeycombing</li> <li>Absence of either patchy involvement or fibroblastic foci, but not both</li> <li>Absence of features against a diagnosis of UIP suggesting an alternate diagnosis (see Not UIP Pattern)</li> </ul> <p>OR</p> <ul style="list-style-type: none"> <li>Honeycomb changes only</li> </ul>
Possible UIP Pattern – need all 3 criteria	<ul style="list-style-type: none"> <li>Patchy or diffuse involvement of lung parenchyma by fibrosis, with or without interstitial inflammation</li> <li>Absence of other criteria for UIP (see UIP Pattern)</li> <li>Absence of features against a diagnosis of UIP suggesting an alternate diagnosis (see Not UIP Pattern)</li> </ul>
Not UIP Pattern – need any of the 6 criteria	<ul style="list-style-type: none"> <li>Hyaline membranes</li> <li>Organizing pneumonia</li> <li>Granulomas</li> <li>Marked interstitial inflammatory cell infiltrate away from honeycombing</li> <li>Predominant airway centered changes</li> <li>Other features suggestive of an alternate diagnosis</li> </ul>

**Combination of HRCT & Surgical Lung Biopsy (determined with multidisciplinary discussion):**

<b>Table 4: Combination of HRCT and Biopsy for Diagnosis of IPF</b>		
HRCT Pattern	Surgical Lung Biopsy Pattern	Diagnosis of IPF
UIP	UIP Probable UIP Possible UIP Not classifiable fibrosis	Yes
	Not UIP	No
Possible UIP	UIP Probable UIP	Yes
	Possible UIP Not classifiable fibrosis	Probable
	Not UIP	No
Inconsistent with UIP	UIP	Possible
	Probable UIP Possible UIP Not classifiable fibrosis Not UI P	No

Shaded areas show combination of HRCT and biopsy patterns that lead to a diagnosis of IPF.

**ESBRIET® (pirfenidone) oral**  
**OFEV® (nintedanib) oral**  
**Pirfenidone oral**

**American Thoracic Society and European Respiratory Society (ATS/ERS):**

Table 5: ATS/ERS Criteria for Diagnosis of IPF in the absence of surgical lung biopsy	
Major Criteria	<ul style="list-style-type: none"> <li>Exclusion of other known causes of ILD (certain drug toxicities, environmental exposure, and connective tissue diseases)</li> <li>Abnormal PFT that include evidence of restriction (reduced VC, often with an associated increase in FEV1/FVC) and impaired gas exchange (increased P(A-a)O<sub>2</sub>, decreased PaO<sub>2</sub> with rest or exercise, or decreased DLCO)</li> <li>Bibasilar reticular abnormalities with minimal ground glass opacities on HRCT scans</li> <li>Transbronchial lung biopsy or BAL showing no features to support an alternative diagnosis</li> </ul>
Minor Criteria	<ul style="list-style-type: none"> <li>Age &gt; 50 years</li> <li>Insidious onset of otherwise unexplained dyspnea on exertion</li> <li>Duration of illness &gt; 3 months</li> <li>Bibasilar, inspiratory crackles (dry or Velcro-type in quality)</li> </ul>
Presence of all Major with as at least 3 of the Minor criteria increases likelihood of a correct clinical diagnosis of IPF	

**American College of Rheumatology (ACR) and European League Against Rheumatism (EULAR) Classification Criteria for Systemic Sclerosis (SSc):**

Table 6: ACR-EULAR Criteria for the classification of Systemic Sclerosis		
These criteria are <b>not</b> applicable to:		
a) Patients having a SSc-like disorder better explaining their manifestations, such as: nephrogenic sclerosing fibrosis, generalized morphea, eosinophilic fasciitis, scleredema diabeticorum, scleromyxedema, erythromyalgia, porphyria, lichen sclerosis, graft versus host disease, and diabetic cheiropathy.		
b) Patients with <i>‘Skin thickening sparing the fingers’</i>		
<b><i>Patients having a total score of 9 or more are classified as having definite systemic sclerosis</i></b>		
Items	Sub-items	Weight score
Skin thickening of the fingers of both hands extending proximal to the metacarpophalangeal joints is a sufficient criterion to classify as having SSc		9
Skin thickening of the fingers <i>(only count the highest score)</i>	Puffy fingers	2
	Sclerodactyly of the fingers (distal to MCP but proximal to the PIPs)	4
Finger-tip lesions <i>(only count the highest score)</i>	Digital Tip Ulcers	2
	Finger Tip Pitting Scars	3
Telangiectasia		2
Abnormal nail-fold capillaries		2
Pulmonary arterial hypertension and/or Interstitial lung Disease (Maximum score is 2)	PAH	2
	ILD	2
Raynaud's phenomenon		3
Scleroderma related antibodies (any of anti-centromere, anti-topoisomerase I [anti-Scl 70], anti-RNA polymerase III) (Maximum score is 3)	Anti-centromere	3
	Anti-topoisomerase I	
	Anti-RNA polymerase III	
Total score		

PHARMACY COVERAGE GUIDELINES  
SECTION: DRUGS

ORIGINAL EFFECTIVE DATE: 1/22/2015  
LAST REVIEW DATE: 8/19/2021  
LAST CRITERIA REVISION DATE: 5/19/2022  
ARCHIVE DATE:

**ESBRIET® (pirfenidone) oral**  
**OFEV® (nintedanib) oral**  
**Pirfenidone oral**

PAH (pulmonary arterial hypertension) is defined as proven PAH by right heart catheterization

ILD (interstitial lung disease) is defined as pulmonary fibrosis on HRCT or chest radiograph, most pronounced in the basilar portions of the lungs, or presence of 'velcro' crackles on auscultation not due to another cause such as congestive heart failure

**Table 7: Definitions of the SSc classification criteria items**

Item	Definition
Skin thickening	Skin thickening or hardening not due to scarring after injury, trauma, etc.
Puffy fingers	Swollen digits - a diffuse, usually non-pitting increase in soft tissue mass of the digits extending beyond the normal confines of the joint capsule. Normal digits are narrowed distally with the tissues following the contours of the digital bone and joint structures. Swelling of the digits obliterates these contours. Not due to other reasons such as inflammatory dactylitis
Finger-tip ulcers or pitting scars	Ulcers or scars distal to or at the PIP joint not thought to be due to trauma. Digital pitting scars are depressed areas at digital tips as a result of ischemia, rather than trauma or exogenous causes.
Telangiectasia	Telangiectasia(e) in a scleroderma like pattern are round and well demarcated and found on hands, lips, inside of the mouth, and/or large matt-like telangiectasia(e). Telangiectasiae are visible macular dilated superficial blood vessels; which collapse upon pressure and fill slowly when pressure is released; distinguishable from rapidly filling spider angiomas with central arteriole and from dilated superficial vessels.
Abnormal nail-fold capillary pattern consistent with SSc	Enlarged capillaries and/or capillary loss with or without peri-capillary hemorrhages at the nail-fold and may be seen on the cuticle.
Pulmonary arterial hypertension	Pulmonary arterial hypertension diagnosed by right heart catheterization according to standard definitions.
Interstitial lung disease	Pulmonary fibrosis on HRCT or chest radiograph, most pronounced in the basilar portions of the lungs, or presence of 'Velcro' crackles on auscultation not due to another cause such as congestive heart failure.
Raynaud's phenomenon	Self-report or reported by a physician with at least a two-phase color change in finger(s) and often toe(s) consisting of pallor, cyanosis and/or reactive hyperemia in response to cold exposure or emotion; usually one phase is pallor.
Scleroderma specific antibodies	Anti-centromere antibody or centromere pattern on antinuclear antibody (ANA) testing; anti-topoisomerase I antibody (also known as anti-Scl70 antibody); or anti-RNA polymerase III antibody. Positive according to local laboratory standards.

**Resources:**

Esbriet (pirfenidone) product information, revised by Genentech, Inc. 07-2019. Available at DailyMed <http://dailymed.nlm.nih.gov>. Accessed January 28, 2020.

---

## ESBRIET® (pirfenidone) oral OFEV® (nintedanib) oral Pirfenidone oral

---

Ofev (nintedanib) product information, revised by Boehringer Ingelheim Pharmaceuticals, Inc. 10-2020. Available at DailyMed <http://dailymed.nlm.nih.gov>. Accessed July 16, 2021.

Varga J. Clinical manifestations and diagnosis of systemic sclerosis (scleroderma) in adults. In: UpToDate, Axford, JS, Curtis R (Eds), UpToDate, Waltham MA.: UpToDate Inc. Available at <http://uptodate.com>. Accessed June 11, 2021.

Varga J. Clinical manifestations, evaluation, and diagnosis of interstitial lung disease in systemic sclerosis (scleroderma). In: UpToDate, King TE, Axford, JS, Hollingsworth H (Eds), UpToDate, Waltham MA.: UpToDate Inc. Available at <http://uptodate.com>. Accessed June 11, 2021.

Denton CP. Overview of the treatment and prognosis of systemic sclerosis (scleroderma) in adults. In: UpToDate, Axford JS, Curtis MR (Ed), UpToDate, Waltham MA.: UpToDate Inc. Available at <http://uptodate.com>. Accessed June 11, 2021.

Varga J. Overview of pulmonary complications of systemic sclerosis (scleroderma). In: UpToDate, King TE, Axford, JS, Hollingsworth H (Eds), UpToDate, Waltham MA.: UpToDate Inc. Available at <http://uptodate.com>. Accessed June 11, 2021.

Varga J, Montesi S. Treatment and prognosis of interstitial lung disease in systemic sclerosis (scleroderma). In: UpToDate, King TE, Axford, JS, Hollingsworth H (Eds), UpToDate, Waltham MA.: UpToDate Inc. Available at <http://uptodate.com>. Accessed June 11, 2021.

Mouthon L, Berezne A, Guillevin L, and Valeyre D. Therapeutic options for systemic sclerosis related interstitial lung disease. *Respiratory Medicine*. 2010; 104, S59-S69. January 28, 2020.

Raghu G, Collard HR, Egan JJ, et al.: An Official ATS/ERS/JRS/ALAT Statement: Idiopathic Pulmonary Fibrosis: Evidence-based Guidelines for Diagnosis and Management. *Am J Resp Crit Care Med* 2011; 183(6):788-824. Accessed May 19, 2020.

Van den Hoogen F, Khanna D, Fransen D, et al.: Classification Criteria for Systemic Sclerosis: An ACR-EULAR Collaborative Initiative. *Arthr Rheum* 2013 November; 65(11): 2737–2747. doi:10.1002/art.38098. Accessed January 27, 2020.

Flaherty KR, Brown KK, Wells AU, et al. Design of the PF-ILD trial: a double-blind, randomized, placebo-controlled phase III trial of nintedanib in patients with progressive fibrosing interstitial lung disease. *BMJ Open Resp Res* 2017;4:e000212. doi:10.1136/bmjresp-2017-000212. Accessed May 19, 2020.

Raghu G, Remy-Jardin M, Myers JL, et al.: Diagnosis of Idiopathic Pulmonary Fibrosis: An Official ATS/ERS/JRS/ALAT Clinical Proactive Guideline. *Am J Respir Crit Care Med* Sep 1, 2018; Vol 198, Iss 5, pp e44–e68. Accessed May 19, 2020.





An Independent Licensee of the Blue Cross Blue Shield Association

**PHARMACY COVERAGE GUIDELINES**  
**SECTION: DRUGS**

**ORIGINAL EFFECTIVE DATE:** 1/22/2015  
**LAST REVIEW DATE:** 8/19/2021  
**LAST CRITERIA REVISION DATE:** 5/19/2022  
**ARCHIVE DATE:**

---

**ESBRIET® (pirfenidone) oral**  
**OFEV® (nintedanib) oral**  
**Pirfenidone oral**

---

Cottin V, Hirani NA, Hotchkin DL, et al. Presentation, diagnosis and clinical course of the spectrum of progressive-fibrosing interstitial lung diseases. *Eur Respir Rev* 2018; 27: 180076 [<https://doi.org/10.1183/16000617.0076-2018>].

Distler O, Volkmann ER, Hoffmann-Vold AM and Maher TM: Current and future perspectives on management of systemic sclerosis-associated interstitial lung disease. *Expert Review of Clin Immunol* 2019, Vol 15: No 10, 1009-1017, DOI: 10.1080/1744666X.2020.1668269. January 28, 2020.

Fischer A, Patel N, Volkmann ER. Interstitial Lung Disease in Systemic Sclerosis: Focus on Early Detection and Intervention. *Open Access Rheumatology: Research and Reviews* 2019;11 283–307. January 28, 2020.

Wollin L, Distler JHW, Redente EF, et al. Potential of nintedanib in treatment of progressive fibrosing interstitial lung diseases. *Eur Respir J* 2019; 54: 1900161 [<https://doi.org/10.1183/13993003.00161-2019>]. Accessed May 18, 2020.

Flaherty KR, Wells AU, Cottin V et al. Nintedanib in Progressive Fibrosing Interstitial Lung Diseases. *NEJM* 2019; 381:1718-1727 DOI: 10.1056/NEJMoa1908681. Accessed May 18, 2020.